

Thai National Guideline for Nuclear Medicine Investigations in Epilepsy

Tawika Kaewchur¹, Wichana Chamroonrat², Tanyaluck Thientunyakit³, Benjapa Khiewvan³, Nantaporn Wongsurawat⁴, Chanisa Chotipanich⁵, Yotin Chinvarun⁶, Krishnapundha Bunyaratavej⁷, Sasithorn Amnuaywattakorn², Nucharee Poon-iad³, Tanawat Sontrapornpol⁸, Panya Pasawang⁸, Supatporn Tepmongkol^{9*}

¹Department of Radiology, PET/CT and Cyclotron Center, Chiang Mai University, Chiang Mai, Thailand

²Division of Nuclear Medicine, Department of Radiology, Ramathibodi Hospital, Mahidol University, Bangkok, Thailand

³Division of Nuclear Medicine, Department of Radiology, Siriraj Hospital, Mahidol University, Bangkok, Thailand

⁴Division of Nuclear Medicine, Department of Radiology, Khon Kaen University, Khon Kaen, Thailand

⁵National Cyclotron and PET Centre, Chulabhorn Hospital, Bangkok, Thailand

⁶Department of Medicine, Phramongkutklao Hospital, Bangkok, Thailand

⁷Department of Surgery, Chulalongkorn University, Bangkok, Thailand

⁸Division of Nuclear Medicine, Department of Radiology, King Chulalongkorn Memorial Hospital, Bangkok, Thailand

⁹Nuclear Medicine Division, Department of Radiology, Chulalongkorn University, Rama IV Rd, Pathumwan, Bangkok, Thailand

ARTICLE INFO

Article type:
Guideline

Article history:

Received: 20 Jan 2021

Revised: 20 Mar 2021

Accepted: 17 Apr 2021

Keywords:

Epilepsy

Nuclear Medicine investigation

SPECT (Single Photon Emission Computed Tomography)

PET (Positron Emission Tomography)

Guideline

ABSTRACT

Epilepsy is a disorder of the brain, which is characterized by recurrent epileptic seizures. These patients are generally treated with antiepileptic drugs. However, more than 30% of the patients become medically intractable and undergo a series of investigations to define candidates for epilepsy surgery. Nuclear Medicine studies using Single Photon Emission Computed Tomography (SPECT) and Positron Emission Tomography (PET) radiopharmaceuticals are among the investigations used for this purpose. Since available guidelines for the investigation of surgical candidates are not up-to-date, The Nuclear Medicine Society of Thailand, The Neurological Society of Thailand, The Royal College of Neurological Surgeons of Thailand, and The Thai Medical Physicist Society has collaborated to develop this Thai national guideline for Nuclear Medicine study in epilepsy. The guideline focuses on the use of brain perfusion SPECT and F-18 fluorodeoxyglucose PET (FDG-PET), the mainly used methods in day-to-day practice. This guideline aims for effective use of Nuclear Medicine investigations by referring physicians e.g. epileptologists and neurologists, radiologists, nuclear medicine physicians, medical physicists, nuclear medicine technologists and technicians.

► Please cite this paper as:

Kaewchur T, Chamroonrat W, Thientunyakit T, Khiewvan B, Wongsurawat N, Chotipanich Ch, Chinvarun Y, Bunyaratavej K, Amnuaywattakorn S, Poon-iad N, Sontrapornpol T, Pasawang P, Tepmongkol S. Thai National Guideline for Nuclear Medicine Investigations in Epilepsy. *Asia Ocean J Nucl Med Biol.* 2021; 9(2): doi:

Introduction

Epilepsy is a disorder of the brain characterized by an enduring predisposition to the generation of epileptic seizures and the neurobiological, cognitive, psychological, and social consequences of this condition.

The definition of epilepsy requires the occurrence of at least one epileptic seizure (1, 2). According to the International League against Epilepsy (ILAE) (1), epilepsy is one of the leading neurological conditions with a worldwide annual incidence of 50 per 100,000 (3).

* Corresponding author: Supatporn Tepmongkol. Nuclear Medicine Division, Department of Radiology, Chulalongkorn University, Rama IV Rd, Pathumwan, Bangkok, Thailand. Tel: +66817743767; Email: supatporn.t@chula.ac.th

© 2021 *mums.ac.ir* All rights reserved.

This is an Open Access article distributed under the terms of the Creative Commons Attribution License (<http://creativecommons.org/licenses/by/3.0>), which permits unrestricted use, distribution, and reproduction in any medium, provided the original work is properly cited.

It profoundly impacts a patient's life in many aspects, including educational success, employment opportunity, driving privilege, psychosocial impact (4-6). Diagnosed epileptic patients are generally managed by a pharmacologic formula with sequential adjustments to keep patient's seizure under control. Unfortunately, more than 30 percent of epileptic patients eventually become medically

intractable despite being managed by an epilepsy specialist (7). These patients are generally referred to multidisciplinary epilepsy centers and had been undergoing a series of investigation to identify the focus of seizure (epileptogenic zone) and determine surgical candidates, which enhance seizure freedom and quality of life of the patients (8). The pathway for epilepsy surgery is shown in Figure 1.

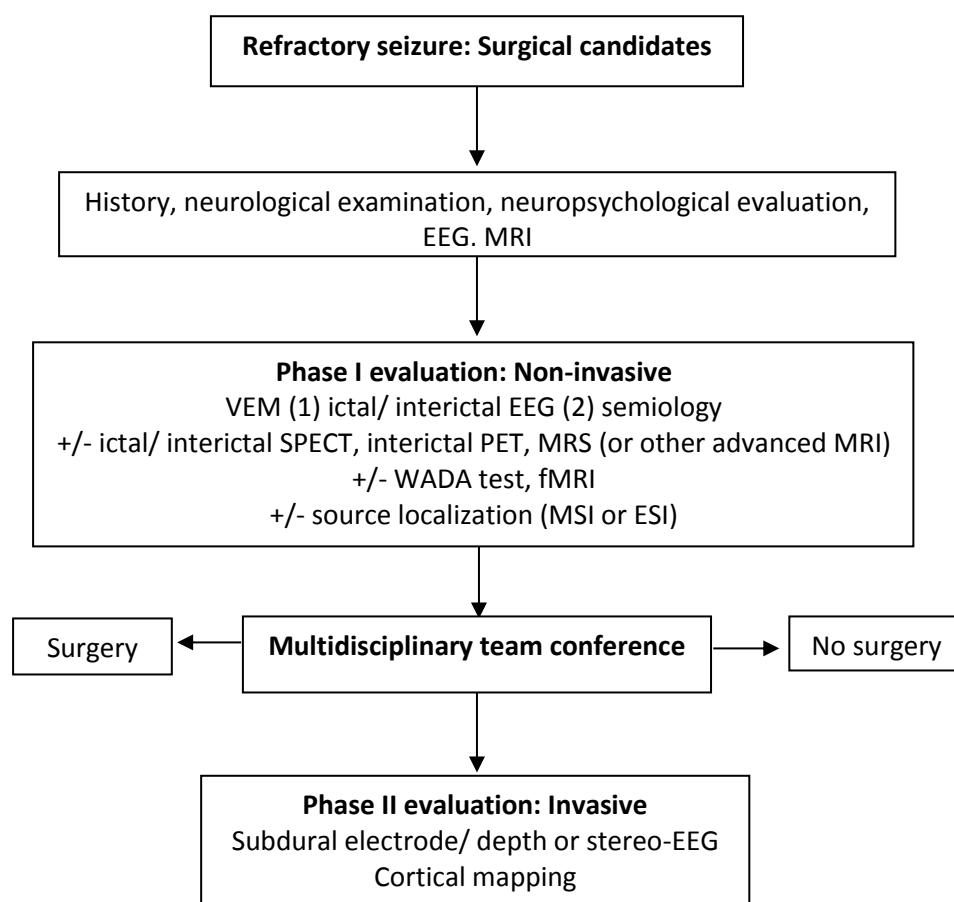


Figure 1. Pathway for epilepsy surgery

EEG = Electroencephalogram
 MRI = Magnetic resonance imaging
 VEM = Video EEG monitoring
 MRS = Magnetic resonance spectroscopy
 WADA = Intracarotid amobarbital procedure
 fMRI = Functional MRI
 MSI = Magnetic source imaging (which use magnetoencephalography as a tool)
 ESI = EEG source imaging

Among many investigations during the pre-surgical evaluation phase for epileptic patients, nuclear medicine technology plays an important role. In combination with other techniques, nuclear medicine technology helps identify the epileptogenic zone, particularly in case of discordant data, magnetic resonance imaging-negative (MRI-negative) epilepsy, focal cortical dysplasia, or extratemporal epilepsy (9-

12). Functional neuroimaging with nuclear medicine tracers using Single Photon Emission Computed Tomography (SPECT) and Positron Emission Tomography (PET) are well-established techniques and are recommended in pre-surgical evaluation by the neuroimaging subcommission of the International League Against Epilepsy (ILAE) and many guidelines (13-17).

The flow of investigations for pre-surgical evaluation is shown in Figure 2. SPECT is a non-invasive functional neuro-imaging method to study regional cerebral blood flow (rCBF) during ictal and interictal phases. Commonly used radiopharmaceuticals are Tc-99m Ethyl Cysteinate Dimer (ECD) and Tc-99m Hexamethylpropyleneamine Oxime (HMPAO). However, Tc-99m ECD is preferred to Tc-99m HMPAO nowadays according to its better gray-white matter ratio and more

practicality of use. During the ictal phase, partial seizure is associated with a transient increase in rCBF. If the radiopharmaceutical is injected early after ictal onset, it represents the “seizure onset zone” which is the area of brain parenchyma that initiates clinical seizure (18) and can be used to localize the epileptogenic zone (10, 19-21). When performed during the interictal phase, the area of decreased rCBF or hypoperfusion represents the “functional deficit zone” (see below).

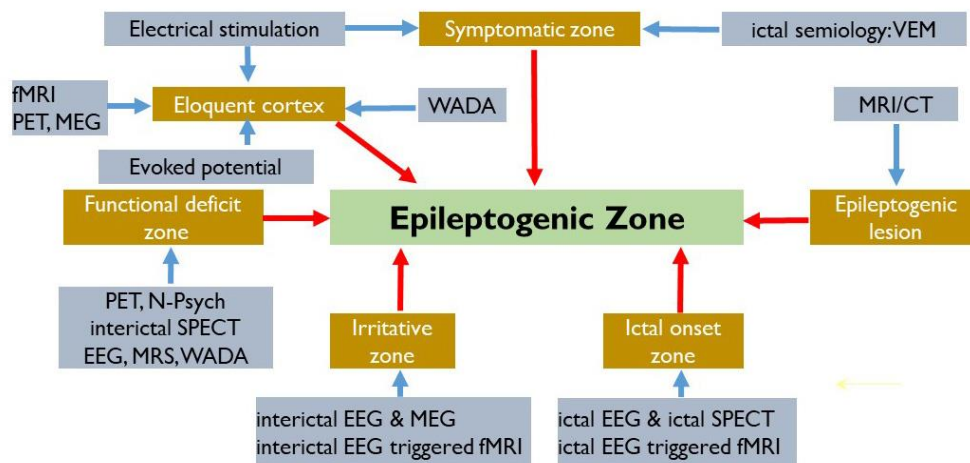


Figure 2. General concepts of the flow of investigation for pre-surgical evaluation in epilepsy patients

- fMRI = Functional MRI
- PET = Positron emission tomography
- MEG = Magnetic encephalography
- VEM = Video EEG monitoring
- CT = Computed tomography
- MRI = Magnetic resonance imaging
- MRS = Magnetic resonance spectroscopy
- EEG = Electroencephalogram
- N-Psych = Neuropsychological tests
- WADA = intracarotid sodium amobarbital procedure (ISAP), used for language and memory testing of each brain hemisphere at a time

PET is another functional neuro-imaging method used in epilepsy. It is mainly used to study the brain glucose metabolism by detection of annihilation photon emitted indirectly by a positron-emitting isotope Fluorine-18 (F-18) labeling with fluoro-deoxyglucose (FDG) or so-called “FDG-PET”. It is usually performed during the interictal phase due to the nature of the radiopharmaceutical used. The abnormality area shows relative hypometabolism than the normal surrounding brain, representing “functional deficit zone”. The functional deficit zone is considered the area of the cortex that has dysfunction during the interictal period (18). It usually encompasses the epileptogenic zone. FDG-PET imaging, especially when performed concurre-

ntly with surface electroencephalogram (EEG) investigation, is of value to localize seizure focus for surgical resection (22-24).

There are also other established SPECT and PET radiopharmaceuticals used for epilepsy, such as I-123 iomazenil (25) and C-11/F-18 flumazenil (26) for evaluating benzodiazepine receptor distribution, C-11 alpha methyl-L-tryptophan (C-11 AMT) for evaluating tryptophan metabolism (27), etc. However, we do not include these radiopharmaceuticals in this guideline because these radiopharmaceuticals are not routinely used.

To use nuclear medicine investigations effectively, all members involved, including referring physicians or epileptologists, radiologists, nuclear medicine professionals,

and technicians should have a consensus on these technologies in general and individual roles. Therefore, representatives from The Nuclear Medicine Society of Thailand, The Neurological Society of Thailand, The Royal College of Neurological Surgeons of Thailand, and The Thai Medical Physicist Society have collaborated to develop this Thai national guideline for nuclear medicine study in epilepsy.

Objectives

1. To identify the role of nuclear medicine studies (brain perfusion SPECT and FDG -PET) in patients with epilepsy

2. To assist referrers in requesting the most appropriate procedure for a given epilepsy patient

3. To identify scientific evidence that is useful to assist nuclear medicine professionals in recommending, performing, interpreting, and reporting the results of nuclear medicine investigations in patients with epilepsy

Indication and relative contra-indication

Indication

The indications for SPECT and PET imaging in epilepsy are shown in table 1.

Table1. Indication for brain perfusion SPECT and FDG-PET in epilepsy

Presurgical evaluation for localization related epilepsies with	Perfusion SPECT	Level of evidence*	FDG-PET	Level of evidence*
Temporal lobe epilepsy (TLE)				
Mesial temporal lobe epilepsy with hippo-campal sclerosis	+	II (24)	+	II (25)
Bilateral mesial temporal lobe epilepsy	+	II (26)	++	II (27)
Suspected dual pathology with mesial temporal sclerosis	++ (to identify the actual seizure onset zone)	II (28)	+	II (25)
Suspected neocortical temporal origin	++	II (28)	+	II (9)
Negative high resolution MRI	+	II (29)	++	I (10, 18)
Extratemporal lobe epilepsy (ETE)				
Suspected extratemporal origin	++ (with SISCOM)	I (30)	+	II (31)
Negative high resolution MRI	++	II (29)	+	II (31)
Postoperative evaluation in case of persistent seizures	+	N/A	++	II (32)

Note :

=++ preferable investigation
 =+ alternative investigation
 N/A = not available

*Levels of evidence (33)

Level I: High quality prospective cohort study with adequate power or systematic review of these studies

Level II: Lesser quality prospective cohort, retrospective cohort study, untreated controls from an RCT, or systematic review of these studies

Level III: Case-control study or systematic review of these studies

Level IV: Case series

Level V: Expert opinion; case report or clinical example; or evidence based on physiology, bench research or "first principles"

Regarding Thai Government reimbursement criteria, both Tc-99m ECD and F-18 FDG can be reimbursed in the following indications as shown in table 2 to pre-surgically identify epileptogenic focus in medically refractory epilepsy and unable to identify epileptogenic focus by MRI images.

Relative contraindication

Pregnancy

Breastfeeding (The lactating patient can resume breastfeeding at 24 hours after F-18 FDG and Tc-99m labeled brain perfusion tracer injection) (28, 29)

Marked elevation of blood sugar in case of FDG-PET

Unable to cooperate (In this context, sedation is needed)

Table 2. Indication for Thai government reimbursement

FDG PET brain scan	Tc-99m ECD brain scan
Reimbursement coverage in:	Reimbursement coverage in:
1.Unclear result from ictal and interictal SPECT AND	1.Unclear result from FDG-PET brain scan AND
2.Discordant MRI brain, EEG, Ictal/Interictal SPECT	2.Discordant MRI brain, EEG, FDG-PET brain scan

Methods

Patient preparation

Achieving the highest effective result, the epileptic patients need to be prepared as follows;

Patient preparation for brain perfusion SPECT (28-30)

Prior to SPECT acquisition

1. Relevant patient history (including any past drug use or trauma), neurologic examination, psychiatric examination, mental status examination, anatomical imaging (For epilepsy, MRI provides higher diagnostic value than CT.), and current medications .
2. Seizure-free for at least 24 hours prior to performing ictal or inter-ictal SPECT.
3. Avoidance of excessive stimulants affecting cerebral blood flow ;
 - a. Food such as caffeine, cola, alcohol, and energy drinks
 - b. Smoking

At SPECT acquisition day

1. Ictal SPECT study
 - a. Evoke stimulus that induces the seizure (e.g. discontinuing antiepileptic drugs, sleep deprivation) may be applied.
 - b. Early tracer injection minimizes misinterpretation problems due to seizure propagation and early switch of perfusion from ictal hyperperfusion to postictal hypoperfusion during brief extratemporal seizures. The optimal injection should be nearest to the seizure onset (less than 30-35 seconds for temporal lobe epilepsy (TLE) and sooner for extratemporal lobe epilepsy (ETE), if possible).
 - c. Epilepsy medical team (neurologist/ epileptologist and nurse) must stand by at the bedside.
2. Interictal SPECT study
 - a. EEG recording is suggested 2 h prior to tracer injection and maintained at least 20 min after injection to ensure "seizure-free status" for image interpretation validity.
 - b. Place the patient in a quiet, dimly-lit room with eyes open and ears unplugged with minimal to no movement or external stimulation for at least 5 minutes before and after the tracer injection .

3. General preparation

- a. Intravenous catheterization should be performed at least 10 minutes prior to injection.
- b. Sedation (31) can be applied in uncooperative patients. Sedation should be given just before image acquisition.
- c. Instruct the patient to void before scanning for patient comfort and to minimize radiation exposure.

Patient Preparation for interictal FDG positron emission tomography (PET)

Prior to FDG-PET acquisition

1. Patients should fast for at least 4 h to allow optimal cerebral FDG uptake not influenced by increased serum glucose levels.
2. Advise the patients to avoid excessive stimulants which may affect brain metabolism;
 - a. Food such as caffeine, cola, alcohol and energy drinks
 - b. Smoking and excessive exercise
3. Diabetic patients need to achieve well-controlled blood glucose from effective treatment.
4. Relevant patient history (including any past drug use or trauma), neurologic examination, psychiatric examination, mental status examination, anatomical imaging (e.g. CT, MRI), and current medications.
5. Seizure-free for at least 48 hours before interictal FDG-PET (32).
6. Recommended medications to be withdrawn were shown in Table 3.

At FDG-PET acquisition day

1. Blood glucose must be checked in every case. Optimal blood glucose level should not exceed 150 mg/dl (30). If blood glucose level exceeds 200 mg/dl, re-scheduling should be considered.
2. Well-hydration is advised.
3. Check the patient's ability to lie still during the whole acquisition time .
4. Stop any medication that interferes with brain glucose metabolism (Table 3).
5. For interictal FDG-PET, EEG recording is suggested 2 h before tracer injection and maintained at least until 20 min after injection to ensure "seizure-free status" for the validity of image interpretation.
6. If a cannula for intravenous administration is required, it should be in place 10 min before FDG administration .

Table 3. Medications interfere FDG uptake

Medication	Duration of withdrawal
Amphetamine	4-6 half-life
Cocaine	
Anesthetics	
Propofol	
Isoflurane	
Barbiturate	
Benzodiazepine	
Corticosteroid	
Neuroleptics (anti-psychotics)	
Haloperidol	
Chlorpromazine	
Cholinesterase inhibitor	
Donepezil	
Rivastigmine	

During FDG injection and uptake period

1. For FDG-PET, place the patient in a quiet, dimly-lit room with eyes open and ears unplugged with minimal to no movement or external stimulation for at least 5 minutes before and after tracer injection
2. The optimal uptake time is 30-60 minutes.
3. Sedation (29, 31) can be applied in uncooperative patients. Sedation should be given just before image acquisition.
4. Instruct the patient to void before scanning for patient comfort and to minimize radiation exposure.
5. Continually monitor vital signs and pulse oximetry during the entire scanning procedure, especially in cases receiving sedation. Emergency back-up should be available.

Co-monitoring/investigation on acquisition day

1. Continuous EEG is recommended before, during, and after SPECT and FDG-PET procedures.
2. For the ictal SPECT study, patients are hospitalized and monitored with video-EEG.
3. For the interictal SPECT and FDG-PET studies, EEG monitoring should start 2 hours before

radiopharmaceutical injection until at least 20 minutes after injection .

Precautions and conscious sedation

Patients with underlying dementia or neurologic deficits need monitoring and special care. Conscious sedation (31) (e.g. short-acting benzodiazepine such as intravenous midazolam) can be applied in uncooperative patients. Patients should fast if sedation use is planned. Sedation should be given at least 20 minutes after radiopharmaceutical administration. The dose of the sedative should be adjusted for elderly patients and children. The pulse oximetry should be monitored during the study because of the possibility of cardiopulmonary depression. Emergency back-up must be available.

Radiopharmaceuticals and radiation Dosimetry**Radiopharmaceuticals (47, 49)**

Recommended radiopharmaceuticals dosage and their characteristics are shown in table 4 and table 5, respectively .

Table 4. Radiopharmaceutical dosage

Radiopharmaceuticals	Children dose	Adult dose
Tc-99m HMPAO	7.4-11.1 MBq/kg (0.2-0.2 mCi/kg)	555-1,110 MBq (15-30 mCi)
	Minimum: 111-185 MBq (3-5 mCi)	Typical: 740 MBq (20 mCi)
Tc-99m ECD	7.4-11.1 MBq/kg (0.2-0.2 mCi/kg)	555-1,110 MBq (15-30 mCi)
	Minimum:111-185 MBq (3-5 mCi)	Typical: 1,110 MBq (30 mCi)
F-18 FDG	5.18-7.4 MBq/kg (0.14-0.20 mCi/kg)	185-740 MBq (5-20 mCi)

Table 5. Radiopharmaceutical characteristics

Agent	Peak brain activity (min)	Blood T1/2	First-pass extraction	Brain uptake (%)	Brain/Bg Ratio	GM:WM ratio	Imaging time	Brain washout
HMPAO	1-2	Slow	70-80%	3.5-7	Lower	2-3:1	30 min-6 hr (optimum 90 min)	15% over 2 min
ECD	2-5	Rapid	>70%	5-7	Higher	4:1	15 min-6 hr (optimum 45 min)	6% per hr
FDG	30-50	Slow	Low	6	Higher	2.5-4.1:1	>30 min	none

Administration timing; Intravenous injection (33)

1. Ictal SPECT: injection should be performed as soon as possible after seizure onset within 35 seconds after clinical or EEG ictal onset (whichever is earlier) for TLE (34) and earlier for ETE.
2. Interictal SPECT: injection should be performed during no clinical or EEG seizure at least 24 hours after the last seizure.

3. Interictal FDG-PET: injection should be performed during no clinical or EEG seizure at least 48 hours after the last seizure (32).

Radiation dosimetry

Radiation dosimetry of SPECT and FDG-PET studies are shown in table 6 and table 7, respectively .

Table 6. Radiation dosimetry in SPECT study in adults and children (49, 54)

	Dose in MBq unit(mCi)	Organ receiving highest dose (mGy/MBq)	Effective dose (mSv/MBq)
Adult			
Tc-99m HMPAO	555-1,110(15-30)	kidney (0.034)	0.0093 mSv
Tc-99m ECD	555-1,110(15-30)	bladder wall (0.05)	0.0077
Children >5year			
Tc-99m HMPAO	32×multiple	thyroid (0.14)	0.027
Tc-99m ECD	51.8× multiple	bladder wall (0.11)	
Multiple (from dosage card*, EANM paediatric dosage card table (v. 1.5.2008))			

Table 7. Radiation dosimetry in FDG-PET/CT in adults and children (26, 31)

	Dose in MBq unit(mCi)	Organ receiving highest dose (mGy/MBq)	Effective dose(mSv/MBq)
Adult			
	185-740(5-20)	bladder wall (0.13)	0.019
Children >5 year			
	14.0× multiple	bladder wall(0.34)	0.056
Multiple (from dosage card*, EANM paediatric dosage card table (v. 1.5.2008))			

Note: Low dose CT scan is used for attenuation correction. The effective dose of a low dose CT scan is about 20 µSv and 220-450 µSv in a high dose or diagnostic CT scan.

SPECT procedure

SPECT: Data acquisition parameters

The optimal time for delay after injection to data acquisition are as follows

1. Tc-99m ECD: 15 minutes -6 hours (optimum at 45 minutes)

2. Tc-99m HMPAO: 30 minutes -6 hours (optimum at 90 minutes)

An excessive delay should be avoided because of radioactive decay (16, 28). Generally, image acquisition should be completed within 4 hours after injection to lower noise and non-specific uptake. The SPECT and SPECT/CT acquisition and reconstruction parameters are summarized in table 8 .

Table 8. SPECT, SPECT/CT acquisition and reconstruction parameters

Instrument	SPECT
Collimator	Fan beam or Parallel hole (LEHR/LEUHR)*
Energy setting	140 keV, 15-20% energy window
Zoom	To gain at least pixel size equal 1/3 to 1/2 of the expected resolution
Nuclide	Tc-99m
Matrix Size	≥ 128×128
Scan mode	Step and shoot or continuous
Rotation per view	≤ 3° (total of 360° rotation)
Time per view	About 15-30 sec/projection (total count 5×10 ⁶ counts)
Scatter correction	Optional
Reconstruction	3D-OSEM/FBP
Slice thickness	Possible 3-5 mm (for maximal pixel resolution)
(if SPECT/CT)	Scout/ Surview/ Topogram CT (optional in some vendors)
CT voltage	120-140 kV
CT current	≤ 30 mA
(if SPECT/CT)	CT (for attenuation correction)
CT voltage	120-140 kV
CT current	≤ 80 mA
Slice thickness	Same as SPECT slice thickness for AC

*Low Energy High Resolution (LEHR) or Low Energy Ultra High Resolution (LEUHR)

**Ordered Subsets Expectation Maximization (OSEM) or Filtered Back Projection (FBP)

Acquisition steps for an individual patient

- Comfortably supine and arms down position on the imaging table

- Immobilization to maintain head position and reduce movement
- Patient's head in the center of the field of view

- The head held straight (not tilted left or right) with the line from the ear to the eye (the canthomeatal line) perpendicular to the detector
- Use the smallest radius of rotation as possible or automated contour setting from patient to detector for imaging to ensure maximum image resolution

SPECT: Data processing

- Review of projection data in cine mode and sonogram for an initial determination of image quality, patient motion, and artifacts
- Reconstruct the data by filtered back-projection (FBP) or iterative reconstructions. The FBP is a common method used because of the more rapidity in processing the data. The iterative method needs longer data processing time, but it can potentially reduce some reconstruction artifact.
- Select type of smoothing filters and their parameters (cutoff and order) to remove high-frequency noise from the ramp filter-generated data in the reconstruction process. For brain perfusion SPECT, low pass filter i.e. Butterworth, Hamming, or Hanning is recommended. The cutoff parameter determines the noise level included in the data.

The more cutoff value used, the more noise produced in the image. For Butterworth filter, the order value determines the slope of the filter. The more the order value is applied, the noise is lesser. The use of cutoff frequency and order values determine the optimal quality of the reconstructed image and should be selected depending on each institution's preference.

- Optimize reconstructing parameters i.e. cutoff, order, iterations, and subset, depending on the injected activity, camera sensitivity, and resolution
- Apply attenuation correction using either calculated (e.g. Chang's method) or measured (e.g. Gadolinium source or CT scan) attenuation
- Apply scatter correction (optional) to improve image signal-to-noise ratio with various methods. The most popular one is triple-energy-window correction.

FDG-PET procedure

PET: Data acquisition parameters

The optimal time for delay after FDG injection to data acquisition is 30–60 minutes. The FDG PET/CT acquisition and reconstruction parameters are summarized in table 9.

Table 9. FDG-PET/CT acquisition and reconstruction parameters

Scout/ Surview/ Topogram CT	
CT voltage	120 kV
CT current	≤ 30 mA
CT	
Scan type	Helical
Rotation time	0.75-1 s
Matrix	512
Slice thickness (mm)	3-5 mm
Slice increments	continuous
Pitch	≤ 1
CT voltage	120-140 kV
CT current time	≤ 50 mAs (Low dose CT), ≤ 250 mAs (Diagnostic CT)
PET	
Energy setting	511 keV, 15-20% energy window
Mode	2D,3D
Scan direction	Towards head
Scan Duration (min/bed)	5-30 (depending on vendors)
Scatter correction	Yes
Reconstruction	Iterative (OSEM*)

*OSEM= ordered subset expectation maximization

Acquisition Steps for an individual patient

- Comfortably supine and arms down position on the imaging table
- Place the patient's head in a holder using foam or folded sheet so that canthomeatal line is vertical
- Immobilization to maintain head position and reduce movement of patient's head in the center of the field of view

PET: Data processing

- Preview image for patient motion and ensure PET and CT images are matched before performing CT attenuation correction.
- Images are reconstructed in the transaxial plane of at least 128X128 matrix size.
- The typical pixel size is 2-4 mm .
- Slice thickness 1-2 pixels.
- Depending on the PET system's resolution, a

final image resolution may vary between 2.5-10 mm full-width at half maximum (FWHM). This typically yields adequate image resolution and signal-to-noise ratios.

- The reconstruction parameters can be varied. Please refer to the manufacturer’s recommendations for best choices of iterations, subsets, and smoothness.

Imaging data display

In general, SPECT and PET are displayed in axial, coronal, and sagittal views. The SPECT or

PET images’ plane or axis could be adjusted according to suspected epileptogenic location, either anterior commissure-posterior commissure (AC-PC) or temporal planes (Figure 3). Examples of axial, coronal, and sagittal brain perfusion SPECT and axial FDG-PET are demonstrated in figure 4 and 5, respectively. (29, 35). The color schemes could be selected according to availability and the reader’s preference. However, the same color scheme should be used for both ictal and interictal SPECT images in the same patient (28, 36, 37).

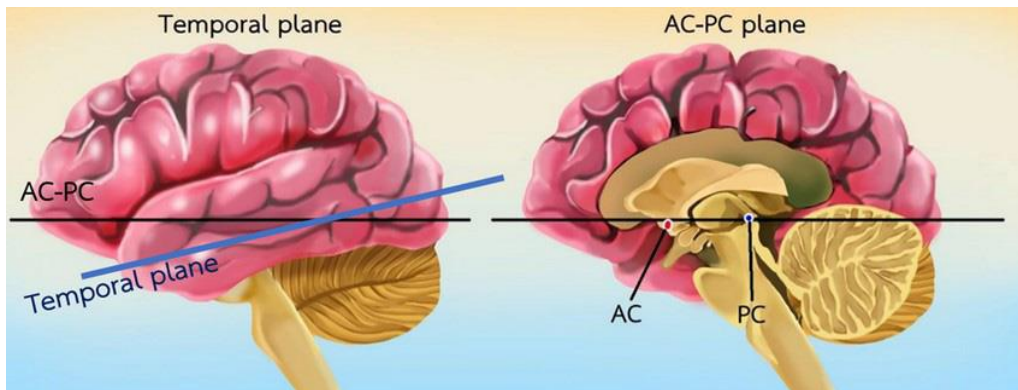


Figure 3. Temporal (left) plane and AC-PC (right) plane

Modified from Supatporn Tepmongkol, ed. Nuclear Medicine Brain Imaging-การตรวจสมองทางเวชศาสตร์นิวเคลียร์, Chulalongkorn University Press, 2018, p.63 (with permission)
 AC-PC = Anterior commissure-posterior commissure

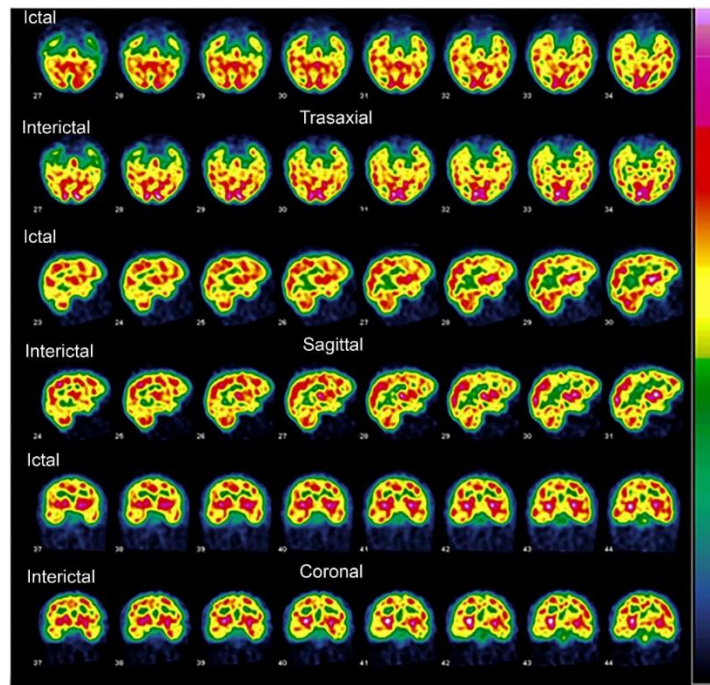


Figure 4. Ictal (EARLY) – Interictal (LATE) French color scale, axial, sagittal, coronal Tc-99m ECD SPECT images with the temporal plane

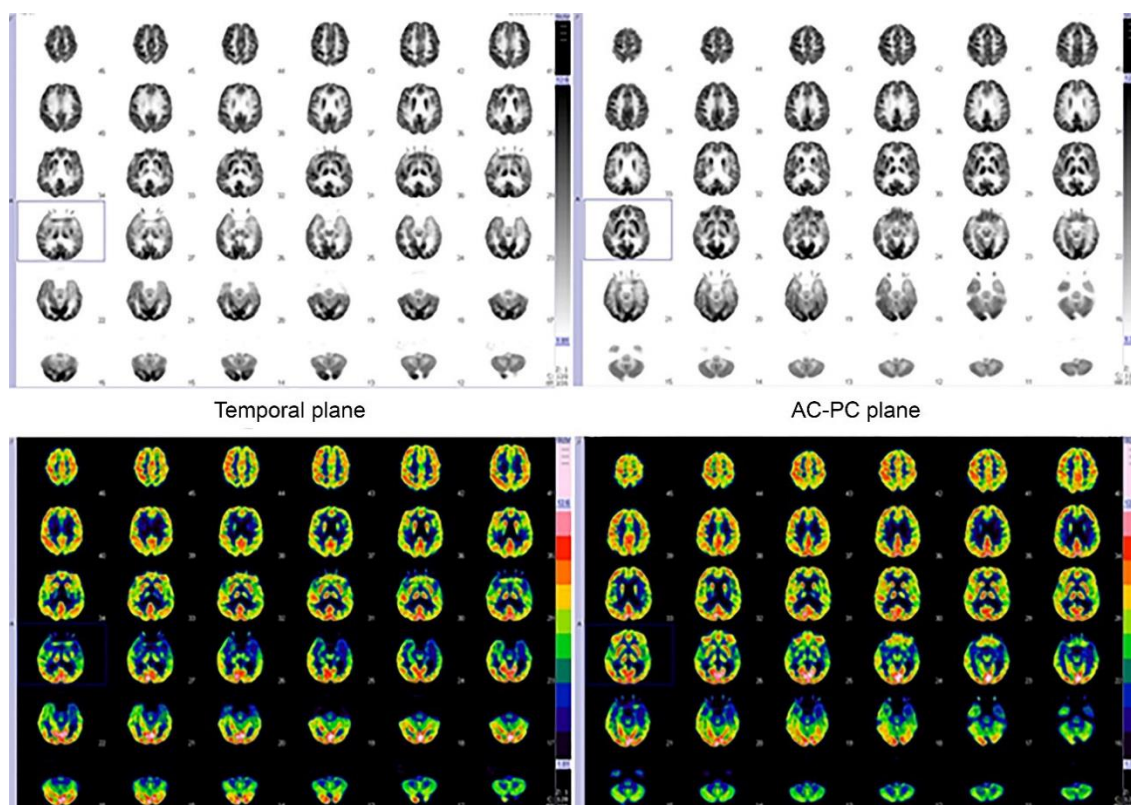


Figure 5. FDG-PET axial image in temporal vs. AC-PC plane in the same patient using grayscale and ten-band color scale

In addition, several nuclear neurology techniques with anatomical imaging (as MRI) co-registration or subtraction (38-40) have proved their advantage with an extra display. Therefore, additional views, images and data could be added. Examples of available techniques with an application for epilepsy include subtraction of ictal and interictal SPECT co-register to MRI (SISCOM), statistical ictal SPECT co-registered to MRI (STATISCOM), etc., some of which will be subsequently detailed.

Interpretation

General consideration

Before interpreting the SPECT or FDG-PET images, the following measures should be confirmed (28, 41).

1. Check the radiopharmaceutical injection time
 - a. Ictal SPECT: within 35 seconds after clinical or EEG ictal onset (whichever is earlier) for temporal lobe epilepsy (TLE) (34) and earlier for extratemporal lobe epilepsy (ETE).
 - b. Interictal SPECT: at least 24 hours after the last seizure.
 - c. Interictal FDG-PET: at least 48 hours after the last seizure (32).
2. Review unprocessed SPECT projection data for the presence and degree of patient motion, target-to-background ratio, and other potential

artifacts using the cinematic display and/or sinogram.

3. Display of the image :

- a. Anterior commissure-Posterior commissure (AC-PC) plane (The plane parallel to the line from anterior commissure to posterior commissure.) should be used if ETE is suspected.
- b. Temporal plane (The plane that is parallel to the temporal lobe.) should be used if TLE is suspected .
- c. If the location of epileptogenicity is unclear, both AC-PC plane and temporal plane should be used.

4. Optimization of color display

Interpretation of SPECT or FDG-PET images should be made together with information from anatomical imaging (MRI is necessary; however, CT is optional). Coregistration and fusion with anatomical imaging can be done to correlate functional change and anatomical details. A careful review of EEG, clinical features at seizure onset, and radiopharmaceutical injection time are necessary for the correct interpretation .

Image interpretation for SPECT

Visual analysis (28)

- The area responsible for epileptogenicity identified by brain perfusion SPECT is called the "seizure onset zone."

- Beware of normal variations
- Interpretation on the workstation screen is recommended to permit interactive adjustment of contrast, background subtraction, and color table.
- A color adjustment can be made by first adjusting the color to see one maximum point in the cortex of ictal SPECT. For interictal SPECT,

the adjustment of color can be made by matching the average perfusion level at the expected non-involved remote cerebral lobes on the ictal SPECT image. For this purpose, a ten-step color scale is suggested.

- Adjustment of color for interpretation by using ten-step color scale as following steps and shown in figure 6 .

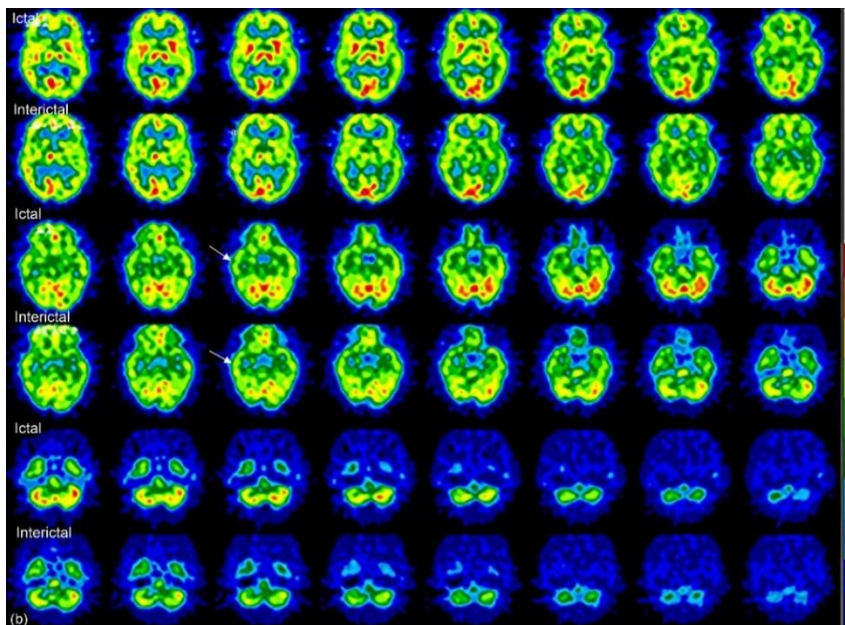
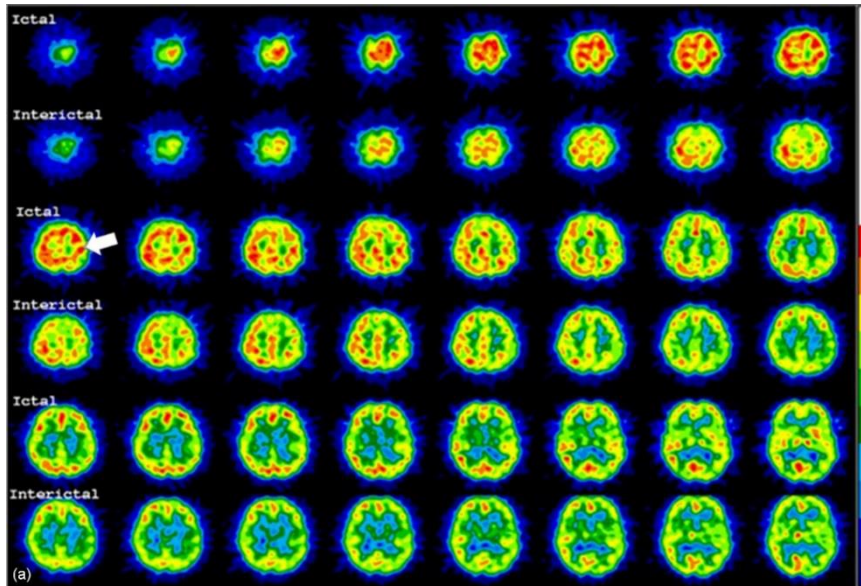


Figure 6. Image color adjustment for ictal and interictal SPECT for visual interpretation. Step 1 (a): Color in ictal phase is adjusted to see a single point of maximum color (in the left parietal cortex in this patient). This is the area of maximum perfusion change. Step 2 (b): Then, adjust the color in interictal phase by matching color in the areas of presumed uninvolved region (the right temporal lobe in this patient) (arrows)

- For TLE: The side of the temporal lobe with maximum change (by comparing the color scale between ictal and interictal phases) is the area of seizure onset.
- For ETE: Seizure onset zone can be diagnosed using the following 3 parameters (42) as shown in Figure 7.

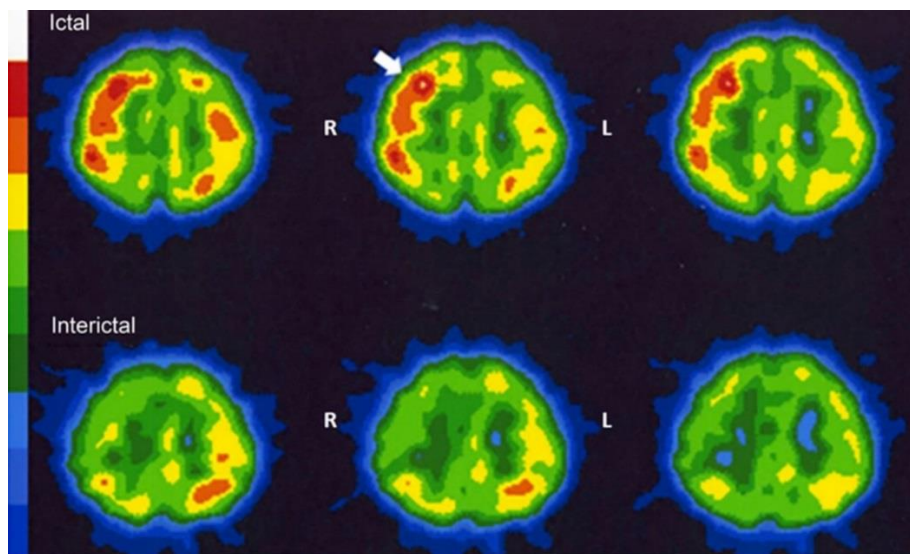


Figure 7. Maximum perfusion (MP) at right frontal lobe is shown in the upper row (arrow); Maximum change (MC) at the right frontal lobe (+30 % change from interictal phase to the ictal phase-from color bar); Maximum extent of hyperperfusion in ictal phase (ME) at the right frontal lobe. The left parietal lobe, which is the remote area from the suspicious region, is used as a reference region for adjustment of perfusion between ictal and interictal phases

Note: Ten-step color scale (color bar) on the left-hand side showing maximum perfusion in white color and minimum perfusion in blue

- Maximum perfusion (MP): MP is identified by manually adjusting ictal or postictal SPECT image to identify the single maximum perfusion point as 100%.
- Maximum change (MC): MC is a parameter that compares ictal (or postictal) and interictal phases. It is identified by visual adjustment of ictal or postictal SPECT image by the method stated in MP, then adjust interictal SPECT image to the same level of average perfusion at the expected non-involved remote cerebral lobes on ictal or postictal SPECT image. Compare the percentage change of cerebral perfusion from interictal to ictal or postictal phase at the involved area. Both positive and negative changes are used as positive for the seizure onset zone.
- Maximum extension (ME): ME in ictal or postictal SPECT is identified by areas of hyperperfusion $\geq 70\%$ cutoff threshold using a ten-step color bar. A region with maximum number of voxels is then defined.
- The seizure onset zone in ETE can then be identified as follows (42);
- In non-lesional MRI findings; if MP and MC are in the same region, the seizure onset zone can be identified with a sensitivity of 26.9%, specificity 92.4% and accuracy of 80.6%.
- In lesional MRI findings; if ME and MRI lesion are located at the same region, the seizure onset zone can be identified with a sensitivity of 41.7%, a specificity of 97.5%, and an accuracy of 88.2%.
- The findings of hyperperfusion of deep gray matter structures on ictal SPECT can also aid in lateralizing the hemispheric side of seizure onset. Ipsilateral basal ganglia or ipsilateral thalamic hyperperfusion has correct lateralization to the same side as cortical seizure onset zone in 77.3% and 80%, respectively (43).

Semiquantitative analysis

Seizure onset zone can be identified by subtracting ictal and interictal SPECT co-register to MRI (SISCOM) or co-register to mean SPECT image (SISCOS). The focus shown on the SISCOM result is the display of the Z-Score map $[(\text{count at the voxel} - \text{mean voxel count})/\text{SD}]$. The Z-Score threshold can be adjusted .

In the case of ictal perfusion greater than interictal perfusion, the focus is called "positive perfusion". Whereas, when ictal perfusion is less than interictal perfusion, the focus is called "negative perfusion". Both positive perfusion or negative perfusion foci could be responsible for epileptogenicity, according to Z-Score (13) as shown in figure 8.

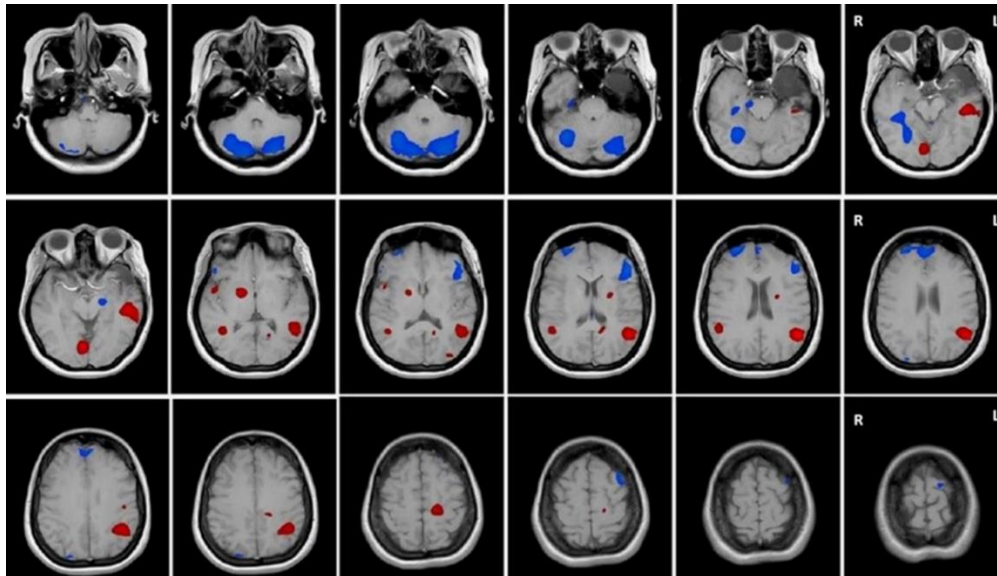


Figure 8. A left temporal lobe epilepsy patient with left hippocampal sclerosis who underwent left anterior temporal lobectomy but continued seizure. Brain perfusion SPECT was then requested and suspected that the ictal onset zone is located just behind the resected area. SISCOM shows that positive perfusion (red color) is at the left posterior temporal region. Since both red (positive perfusion) and blue (negative perfusion) areas can be ictal onset zone, correlation with clinical and EEG data. In this case, it concluded that the left posterior temporal red area is most likely to be the ictal onset zone

Note: Areas of positive perfusion (red color) and negative perfusion (blue color) in SISCOM represent areas of Z-score change of 2 to 10 and -2 to -10, respectively

Image interpretation for FDG-PET

The area of hypometabolism identified by brain FDG-PET is called the “functional deficit zone”. This region may or may not be responsible for epileptogenicity. However, if there is a single hypometabolic cortical focus, it is a high possibility to be responsible for epileptogenicity.

- For temporal lobe epilepsy, hypometabolism on one temporal lobe can localize epileptic focus in 60-100% (13).
- For extratemporal lobe epilepsy, resection of focal hypometabolism in a single lobe results in seizure freedom. Additional hypometabolism in other lobes of the ipsilateral cerebral hemisphere or the contralateral hemisphere results in poorer surgical outcomes than a single lobe hypometabolism (44).

Combined SPECT and FDG-PET

If the findings of brain perfusion SPECT and brain FDG-PET are congruent, it results in more seizure freedom if resection is performed at this site in extratemporal lobe epilepsy (45).

Multimodalities imaging and coregistration

General consideration

As mentioned in the previous interpretation section, the combination of coregistration images of ictal and interictal perfusion SPECT or

FDG-PET with anatomical imaging studies (CT or MRI) results in higher accuracy for detecting epileptogenic focus in temporal lobe epilepsy in comparison with visual assessment only (13). The coregistration of ictal-interictal SPECT images can increase visual interpretation sensitivity from about 40%-70% for TLE and 35%-55% for ETE in patients with normal MRI (46). Significantly higher successful localization of epileptogenic focus was obtained by SISCOM than side-by-side visual inspection of ictal and interictal images (88.2% vs. 39.2%). Furthermore, epilepsy surgery patients whose SISCOM localization was concordant with the surgical site were more likely to have an excellent outcome (63.5%) as compared to patients with non concordance (20%) (47).

Coregistration techniques in Brain Perfusion SPECT

There are two basic techniques for coregistration.

1. Subtraction of ictal-interictal SPECT co-registered to interictal or mean SPECT (SISCOS)

Several methods have been proposed to compute the difference between ictal, and interictal SPECT scans in the same patient using co-registered ictal and interictal SPECT images. An example for free, available methods which has been used for this purpose is;

- Ictal-Interictal SPECT Analysis by statistical

parametric mapping (ISAS) is the technique developed by Yale University (<http://spect.yale.edu>) to compute the difference between an ictal and interictal SPECT scan in the same patient using statistical parametric mapping (SPM). The differences of the ictal/inter-ictal comparison are evaluated against a healthy normal database to determine the normal expected variation, therefore, significant increases and decreases in cerebral blood flow between the ictal and interictal SPECT can be identified (48). The difference of ictal-interictal SPECT identified a single unambiguous region of seizure onset in 71% of mesial temporal and 83% of neocortical epilepsy cases, and the localization was correct in all cases (100%) (13).

- Apart from the freely available software, there are also commercially available software/appli-

cations for coregistration ictal and interictal SPECT images to subtract and identify the areas with a maximum difference for assisting in localization of epileptogenic focus, for example, Q.Brain (www.gehealthcare.com) as in Figure 9, CURRY software (<https://compumedicsneuroscan.com>), MedView software (<https://medimage.com>), NeuroQ (www.syntermed.com).

2. Subtraction Ictal-interictal SPECT Coredgistered with MRI (SISCOM)

SISCOM is the method widely used to combine functional information derived from perfusion SPECT with structural anatomy from MRI to identify the areas of regional activation of the brain during a seizure.

The input data required for SISCOM are ictal SPECT, interictal SPECT, and 3D MRI images. The example of SISCOM image is shown in Figure 10 .

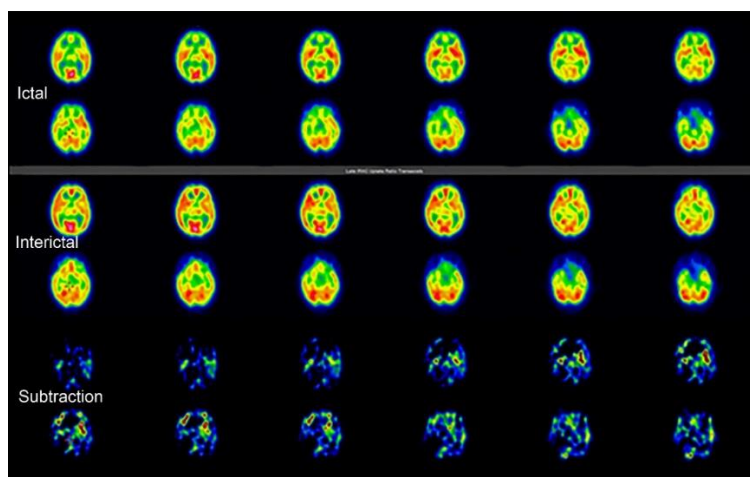


Figure 9. Example of ictal SPECT (two top rows), interictal SPECT (two middle rows), and ictal-interictal subtraction SPECT images (two bottom rows) in the same case using Q.Brain software to identify the maximum difference of radioactivity count statistics between both SPECT image

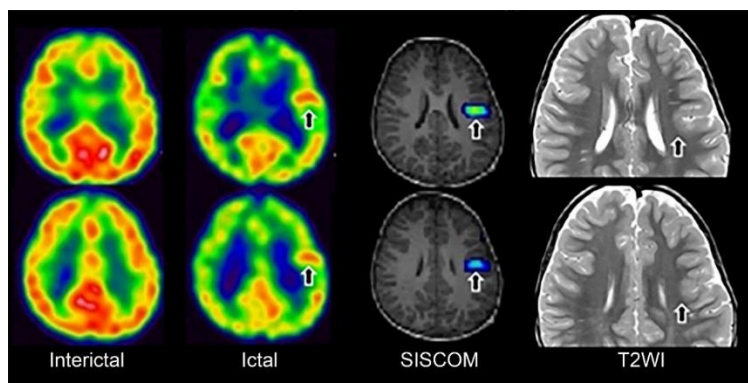


Figure 10. An imaging dataset of a three-year-old boy with intractable epilepsy, including interictal SPECT images (1st column), ictal SPECT images (2nd column), SISCOM images with ictal-interictal subtraction image fused with T1-weighted MRI (3rd column), and T2-weighted MRI images (4th column). In this case, the abnormal area identified by SISCOM technique (arrow) corresponds to focal cortical dysplasia type II as demonstrated in T2-weighted MRI images (arrow). Image courtesy of Yukio Kimura, M.D., National Center of Neurology and Psychiatry, Japan (with permission)

Remarks

There is still no consensus regarding the optimal cutoff Z-score and varies from 1.5 to 3 (49-51). SISCOM images often display multiple hyperperfusion areas, including the areas of ictal onset and seizure propagation. In such cases, detecting the epileptogenic focus is difficult. Therefore, the optimal Z-score used for interpretation with individual adjustment may be considered, especially noting the clinical context and results from other investigations .

Coregistration techniques of FDG-PET and MRI

There are several software applications for the coregistration of FDG-PET images to localize the focal glucose hypometabolic area with structural anatomy on an MRI. Examples include free software e.g. Statistical Parametric Mapping (SPM, www.fil.ion.ucl.ac.uk/SPM/) and NEUROSTAT (<https://neurostat.neuro.utah.edu/>), and commercial software e.g. PNeuro (PMOD Technologies), MIMNeuro (MIM Software Inc), NeuroQ (Syntermed) and software applications provided by the PET scanner or PACS companies. However, a higher sensitivity of SISCOM (100% vs. 51%) of FDG-PET co-registered with MRI in correlation with intracranial EEG results in 53 patients has been reported (52).

Reporting format

Specific identification of each patient, referring clinician, date and time of the study, and the reporting physician's signature must be provided in the report as part of quality assurance. However, the reporting physician's role in gathering this information may now be less burdensome in light of current modernized reporting systems. The responsibility of the reporting physician is to correctly match this part to the body of the report. The recommended structural body of the report for both SPECT or FDG-PET brain (28, 29, 35-37) includes four major portions as follows.

- History: The relevant history should be noted along with an indication of the study, for example, type of seizure, suspected location either TLE or ETE, recent medication, seizure-free interval, and last seizure type.

- Techniques:

- Radiopharmaceutical type and dosage: Injection interval of radiopharmaceutical and normal saline flushing after clinical or EEG seizure onset

- Detailed imaging techniques, processing techniques, and concurrent EEG result (if any) should be mentioned, including imaging quality and limitations. If certain specific software or

anatomical co-registration/subtraction is utilized, it should be additionally detailed.

- Ancillary drugs, if used (e.g. Type and time of sedative drugs)

- Serum glucose level for FDG-PET

- Findings:

- SPECT (ictal, interictal or subtraction) or FDG-PET pattern should be mentioned. If a suspected epileptogenic lesion is found, its location, extension, and severity should be reported. Semiquantitative results (if done) e.g. percentage of perfusion change from ictal-interictal subtraction images or Z-score. Correlative imaging findings, if available, e.g. MRI, CT should be mentioned.

- Interpretations/Impressions/Conclusions: The final impression from imaging data should be interpreted along with available clinical data and correlative imaging data. If they seem discordant, direct discussion with the multidisciplinary team would be the best (if possible) or provide further recommendations.

Pitfalls and errors (28, 36, 53-58)

1. Biological factors

a. Unexpected brain activity from external stimuli

b. Drug interference with cerebral blood flow

c. The effects from sedation at the time of injection

d. Time of tracer injection in ictal SPECT

e. Subclinical seizure in interictal SPECT or FDG-PET

f. Anatomical variations (e.g. focal cortical malformation)

g. Generalized brain hypometabolism due to hyperglycemia

2. Technical factors

a. Motion artifact can cause blurring of the image. For FDG-PET, it can be solved by excluding data in some dynamic frames in list mode. For SPECT, motion artifact can be solved by motion correction software, which varies among vendors. However, only motion in craniocaudal direction (or Y-axis) can be corrected. If there is motion in other directions, re-acquisition is recommended.

b. Misregistration artifact between SPECT or PET and CT from patient movement can be corrected by software or hardware in some vendor or repeat data collection if there is obvious head movement .

c. Motion Inappropriate processing (e.g. Reconstruction method)

d. Attenuation artifact from intracranial electrode insertion

e. Non-continuous color table display

f. Level of contrast and background subtraction

g. Inappropriate Z-score thresholding

h. Suboptimal image display plane eg. Not true AC-PC plane or temporal plane, asymmetrical temporal plane

i. Partial volume effect on the corrected image

List of abbreviations

AC = Attenuation correction

AC-PC = Anterior commissure-posterior commissure

Bg = Background

CT = Computed tomography

EANM = European Association of Nuclear Medicine

ECD = Ethyl cysteinyl dimer

EEG = Electroencephalogram

ESI = EEG source imaging

ETE = Extratemporal lobe epilepsy

FBP = Filtered back projection

FCD = focal cortical dysplasia

FDG = Fluorodeoxy glucose

fMRI = Functional MRI

FWHM = Full-width at half maximum

GM = Gray matter

Gy = Gray

HMPAO = Hexamethylpropylene amine oxime

ILAE = International League Against Epilepsy

ISAS = ictal-interictal SPECT analyzed by statistical parametric mapping (SPM)

keV = Kiloelectronvolt

kV = Kilovolt

LEHR = Low energy high resolution

LEUHR = Low energy ultra-high resolution

mA = Milliampere

mAs = milliamperesecond

MBq= MegaBequerel

mCi = milliCurie

MEG = Magnetic encephalography

MRI = Magnetic resonance imaging

MRS = Magnetic resonance spectroscopy

MSI = Magnetic source imaging

N-Psych = Neuropsychological tests

OSEM= ordered subset expectation maximization

PET = Positron emission tomography

rCBF = regional cerebral blood flow

SISCOM = Subtraction ictal SPECT co-register to MRI

SISCOS = Subtraction ictal SPECT co-register to SPECT

SNM = Society of Nuclear Medicine

SPECT = Single photon emission computed tomography

SPM = statistical parametric mapping

STATISCOM = statistical ictal SPECT coregistered to MRI

Sv = Sievert

TLE = Temporal lobe epilepsy

VEM = Video EEG monitoring

WADA = Intracarotid amobarbital procedure

WM = White matter

Acknowledgement

The authors thank Mrs. Barbara Metzler for manuscript proofreading. We also would like to thank Global Medicine Solution (GMS) Thailand, Siemens Healthcare, and Premier Business Inter for their financial support in the guideline development .

References

1. Fisher RS, van Emde Boas W, Blume W, Elger C, Genton P, Lee P, et al. Epileptic seizures and epilepsy: definitions proposed by the International League Against Epilepsy (ILAE) and the International Bureau for Epilepsy (IBE). *Epilepsia*. 2005; 46(4):470-2.
2. Fisher RS, Acevedo C, Arzimanoglou A, Bogacz A, Cross JH, Elger CE, et al. ILAE official report: a practical clinical definition of epilepsy. *Epilepsia*. 2014; 55(4):475-82.
3. Ngugi AK, Kariuki SM, Bottomley C, Kleinschmidt I, Sander JW, Newton CR. Incidence of epilepsy: a systematic review and meta-analysis. *Neurology*. 2011; 77(10):1005-12.
4. Burneo JG, Tellez-Zenteno J, Wiebe S. Understanding the burden of epilepsy in Latin America: a systematic review of its prevalence and incidence. *Epilepsy Res*. 2005; 66(1-3):63-74.
5. Ngugi AK, Bottomley C, Kleinschmidt I, Sander JW, Newton CR. Estimation of the burden of active and life-time epilepsy: a meta-analytic approach. *Epilepsia*. 2010; 51(5):883-90.
6. Trinkaus E, Kwan P, Lee B, Dash A. Epilepsy in Asia: Disease burden, management barriers, and challenges. *Epilepsia*. 2019; 60 Suppl 1:7-21.
7. Kwan P, Brodie MJ. Early identification of refractory epilepsy. *N Engl J Med*. 2000; 342(5):314-9.
8. Anurat K, Khongkhatithum C, Pattanaprateep O, Chamroonrat W, Boongird A, Visudtibhan A, et al. Cost-effectiveness analysis of epilepsy surgery in children and adolescents with drug resistant focal epilepsy at three years in a tertiary care epilepsy center in Thailand. *Journal of Clinical Neuroscience*. 2020; 79:163-8.
9. Ergun EL, Saygi S, Yalnizoglu D, Oguz KK, Erbas B. SPECT-PET in Epilepsy and Clinical Approach in Evaluation. *Semin Nucl Med*. 2016; 46(4):294-307.
10. Joo EY, Seo DW, Hong SC, Hong SB. Functional neuroimaging findings in patients with lateral and mesio-lateral

- temporal lobe epilepsy; FDG-PET and ictal SPECT studies. *J Neurol*. 2015; 262(5):1120-9.
11. Kogias E, Klingler JH, Urbach H, Scheiwe C, Schmeiser B, Doostkam S, et al. 3 Tesla MRI-negative focal epilepsies: Pre-surgical evaluation, postoperative outcome and predictive factors. *Clin Neurol Neurosurg*. 2017; 163:116-20.
 12. Zijlmans M, Zweiphenning W, van Klink N. Changing concepts in pre-surgical assessment for epilepsy surgery. *Nat Rev Neurol*. 2019.
 13. Theodore WH. Pre-surgical Focus Localization in Epilepsy: PET and SPECT. *Semin Nucl Med*. 2017; 47(1):44-53.
 14. Vander Borght T, Laloux P, Maes A, Salmon E, Goethals I, Goldman S, et al. Guidelines for brain radionuclide imaging. Perfusion single photon computed tomography (SPECT) using Tc-99m radiopharmaceuticals and brain metabolism positron emission tomography (PET) using F-18 fluorodeoxyglucose. The Belgian Society for Nuclear Medicine. *Acta Neurol Belg*. 2001; 101(4):196-209.
 15. Sidhu MK, Duncan JS, Sander JW. Neuroimaging in epilepsy. *Curr Opin Neurol*. 2018; 31(4):371-8.
 16. Guidelines for neuroimaging evaluation of patients with uncontrolled epilepsy considered for surgery. Commission on Neuroimaging of the International League Against Epilepsy. *Epilepsia*. 1998; 39(12):1375-6.
 17. Fernandez S, Donaire A, Seres E, Setoain X, Bargallo N, Falcon C, et al. PET/MRI and PET/MRI/SISCOM coregistration in the pre-surgical evaluation of refractory focal epilepsy. *Epilepsy Res*. 2015; 111:1-9.
 18. Carreño M, Lüders HO. General Principles of Presurgical Evaluation. In: Lüders HO, Comair YG, editors. *Epilepsy Surgery*. Second ed. Philadelphia: Lippincott, Williams & Wilkins; 2001. p. 185-200.
 19. Jones AL, Cascino GD. Evidence on Use of Neuroimaging for Surgical Treatment of Temporal Lobe Epilepsy: A Systematic Review. *JAMA Neurol*. 2016; 73(4):464-70.
 20. Juhasz C, John F. Utility of MRI, PET, and ictal SPECT in pre-surgical evaluation of non-lesional pediatric epilepsy. *Seizure*. 2019.
 21. Chen T, Guo L. The role of SISCOM in preoperative evaluation for patients with epilepsy surgery: A meta-analysis. *Seizure*. 2016; 41:43-50.
 22. Royal College of Physicians of London, Royal College of Physicians and surgeons of Glasgow, Royal College of Physicians of Edinburgh, The Royal College of Radiologists, British nuclear medicine Society, committee. Aorsa. Evidence-based indications for the use of PET-CT in the United Kingdom 2016: The Royal College of Radiologists; 2016 [Available from: www.rcr.ac.uk/publication/evidence-based-indications-use-pet-ct-united-kingdom-2016].
 23. Oldan JD, Shin HW, Khandani AH, Zamora C, Benefield T, Jewells V. Subsequent experience in hybrid PET-MRI for evaluation of refractory focal onset epilepsy. *Seizure*. 2018; 61:128-34.
 24. Montaz-Rosset MS, Scholly J, Voulleminot P, Severac F, Hirsch E, Valenti-Hirsch MP, et al. Comparison of Functional Deficit Zone Defined by FDG PET to the Epileptogenic Zones Described in Stereo-Electroencephalograph in Drug-Resistant Epileptic Patients Treated by Surgery. *Clin Nucl Med*. 2019; 44(7):526-31.
 25. Fujimoto A, Okanishi T, Kanai S, Sato K, Itamura S, Baba S, et al. Double match of (18)F-fluorodeoxyglucose-PET and ioma zenil-SPECT improves outcomes of focus resection surgery. *Acta Neurochir (Wien)*. 2018; 160(9):1875-82.
 26. Hodolic M, Topakian R, Pichler R. (18)F-fluorodeoxyglucose and (18)F-flumazenil positron emission tomography in patients with refractory epilepsy. *Radiol Oncol*. 2016; 50(3):247-53.
 27. Chugani DC. α -methyl-L-tryptophan: mechanisms for tracer localization of epileptogenic brain regions. *Biomark Med*. 2011; 5(5):567-75.
 28. Kapucu OL, Nobili F, Varrone A, Booij J, Vander Borght T, Nagren K, et al. EANM procedure guideline for brain perfusion SPECT using ^{99m}Tc-labelled radiopharmaceuticals, version 2. *Eur J Nucl Med Mol Imaging*. 2009; 36(12):2093-102.
 29. Varrone A, Asenbaum S, Vander Borght T, Booij J, Nobili F, Nagren K, et al. EANM procedure guidelines for PET brain imaging using [18F]FDG, version 2. *Eur J Nucl Med Mol Imaging*. 2009; 36(12):2103-10.
 30. Waxman AD HK, Lewis, DH, Herscovitch P, Minoshima S, Ichise M, et al. Society of Nuclear Medicine Procedure Guideline for FDG PET Brain Imaging Version 1.0. 2009.
 31. Varrone A, Asenbaum S, Vander Borght T, Booij J, Nobili F, Nagren K, et al. EANM procedure guidelines for PET brain imaging using [18F]FDG, version 2. *Eur J Nucl Med Mol Imaging*. 2009; 36(12):2103-10.
 32. Tepmongkol S, Srikijvilaiikul T, Vasavid P. Factors affecting bilateral temporal lobe hypometabolism on 18F-FDG PET brain

- scan in unilateral medial temporal lobe epilepsy. *Epilepsy Behav.* 2013; 29(2):386-9.
33. Mettler Jr. MD MPH FA, Guiberteau MD FACR FACNM, Milton J. *Essentials of Nuclear Medicine and Molecular Imaging* Elsevier; 7 edition; 2018.
 34. Ramchuankiat S, Jarumaneeroj P, Limotai C, Tepmongkol S, Rakvongthai Y. Impact of injection time on migration of SPECT seizure onset in temporal lobe epilepsy. *Conf Proc IEEE Eng Med Biol Soc.* 2017; 2017:1465-8.
 35. Yoshida T, Ha-Kawa S, Yoshimura M, Nobuhara K, Kinoshita T, Sawada S. Effectiveness of treatment with donepezil hydrochloride and changes in regional cerebral blood flow in patients with Alzheimer's disease. *Annals of nuclear medicine.* 2007; 21(5):257-65.
 36. Juni JE, Waxman AD, Devous MD, Sr., Tikofsky RS, Ichise M, Van Heertum RL, et al. Procedure guideline for brain perfusion SPECT using (99m)Tc radiopharmaceuticals 3.0. *J Nucl Med Technol.* 2009; 37(3):191-5.
 37. Thomsen G, Knudsen GM. Procedure guideline for brain perfusion SPECT using 99mTc radiopharmaceuticals 3.0. *J Nucl Med Technol.* 2010; 38(4):209.
 38. Juhasz C, John F. Utility of MRI, PET, and ictal SPECT in pre-surgical evaluation of non-lesional pediatric epilepsy. *Seizure.* 2019.
 39. Perissinotti A, Setoain X, Aparicio J, Rubi S, Fuster BM, Donaire A, et al. Clinical Role of Subtraction Ictal SPECT Coregistered to MR Imaging and (18) F-FDG PET in Pediatric Epilepsy. *J Nucl Med.* 2014; 55(7):1099-105.
 40. Long Z, Hanson DP, Mullan BP, Hunt CH, Holmes DR, 3rd, Brinkmann BH, et al. Analysis of Brain SPECT Images Coregistered with MRI in Patients with Epilepsy: Comparison of Three Methods. *J Neuroimaging.* 2018; 28(3):307-12.
 41. Society of Nuclear Medicine Procedure Guideline for FDG PET Brain Imaging [Internet]. Society of Nuclear Medicine. 2009. Available from: <http://www.snm.org/>
 42. Tepmongkol S, Tangtrairattanakul K, Lerdlum S, Desudchit T. Comparison of brain perfusion SPECT parameters accuracy for seizure localization in extratemporal lobe epilepsy with discordant pre-surgical data. *Ann Nucl Med.* 2015; 29(1):21-8.
 43. Sojkova J, Lewis PJ, Siegel AH, Siegel AM, Roberts DW, Thadani VM, et al. Does asymmetric basal ganglia or thalamic activation aid in seizure foci lateralization on ictal SPECT studies? *Journal of nuclear medicine: official publication, Society of Nuclear Medicine.* 2003; 44(9):1379-86.
 44. Wong CH, Bleasel A, Wen L, Eberl S, Byth K, Fulham M, et al. Relationship between preoperative hypometabolism and surgical outcome in neocortical epilepsy surgery. *Epilepsia.* 2012; 53(8):1333-40.
 45. Chandra PS, Vaghania G, Bal CS, Tripathi M, Kuruwale N, Arora A, et al. Role of concordance between ictal-subtracted SPECT and PET in predicting long-term outcomes after epilepsy surgery. *Epilepsy Res.* 2014; 108(10):1782-9.
 46. Sulc V, Stykel S, Hanson DP, Brinkmann BH, Jones DT, Holmes DR, 3rd, et al. Statistical SPECT processing in MRI-negative epilepsy surgery. *Neurology.* 2014; 82(11):932-9.
 47. O'Brien TJ, So EL, Mullan BP, Hauser MF, Brinkmann BH, Bohnen NI, et al. Subtraction ictal SPECT co-registered to MRI improves clinical usefulness of SPECT in localizing the surgical seizure focus. *Neurology.* 1998; 50(2):445-54.
 48. Chang DJ, Zubal IG, Gottschalk C, Necochea A, Stokking R, Studholme C, et al. Comparison of statistical parametric mapping and SPECT difference imaging in patients with temporal lobe epilepsy. *Epilepsia.* 2002; 43(1):68-74.
 49. Newey CR, Wong C, Wang ZI, Chen X, Wu G, Alexopoulos AV. Optimizing SPECT SISCOM analysis to localize seizure-onset zone by using varying z scores. *Epilepsia.* 2013; 54(5):793-800.
 50. De Coster L, Van Laere K, Cleeren E, Baete K, Dupont P, Van Paesschen W, et al. On the optimal z-score threshold for SISCOM analysis to localize the ictal onset zone. *EJNMMI Res.* 2018; 8(1):34.
 51. Kimura Y, Sato N, Ito K, Kamiya K, Nakata Y, Saito Y, et al. SISCOM technique with a variable Z score improves detectability of focal cortical dysplasia: a comparative study with MRI. *Ann Nucl Med.* 2012; 26(5):397-404.
 52. Desai A, Bekelis K, Thadani VM, Roberts DW, Jobst BC, Duhaime AC, et al. Interictal PET and ictal subtraction SPECT: sensitivity in the detection of seizure foci in patients with medically intractable epilepsy. *Epilepsia.* 2013; 54(2):341-50.
 53. Duncan R, Patterson J, Roberts R, Hadley DM, Bone I. Ictal/postictal SPECT in the pre-surgical localisation of complex partial seizures. *J Neurol Neurosurg Psychiatry.* 1993; 56(2):141-8.
 54. Goffin K, Dedeurwaerdere S, Van Laere K,

- Van Paesschen W. Neuronuclear assessment of patients with epilepsy. *Semin Nucl Med.* 2008; 38(4):227-39.
55. Henry TR, Van Heertum RL. Positron emission tomography and single photon emission computed tomography in epilepsy care. *Semin Nucl Med.* 2003; 33(2):88-104.
56. Lin E, Alavi A. PET and PET/CT: A Clinical Guide: Thieme; 2009.
57. Matsuda H, Ohnishi T, Asada T, Li ZJ, Kanetaka H, Imabayashi E, et al. Correction for partial-volume effects on brain perfusion SPECT in healthy men. *J Nucl Med.* 2003; 44(8):1243-52.
58. Rowe CC, Berkovic SF, Austin MC, Saling M, Kalnins RM, McKay WJ, et al. Visual and quantitative analysis of interictal SPECT with technetium-99m-HMPAO in temporal lobe epilepsy. *J Nucl Med.* 1991; 32(9):1688-94